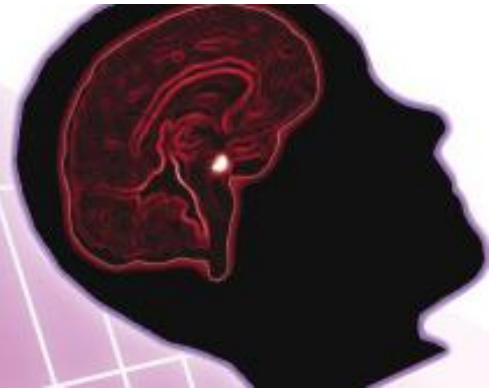



FOURTEENTH  
CLINICOPATHOLOGICAL  
CONFERENCE ON  
PITUITARY DISEASE



# Programme & Abstract Book

Educational grants have been provided from:  Merck Serono  
Living science, transforming lives

 FERRING  
PHARMACEUTICALS

 STORZ  
KARL STORZ – ENDOSKOPE

## Programme

**8:30 Registration and Coffee**

**9:15 Welcome and Introduction**  
Dr Stephanie E Baldeweg & Mr Michael Powell

**9:20 Three Cases**

**Case 1: Cushing's?**

*Author(s): C.Otti, N.M. Martin, N. Mendoza, F. Roncaroli, A. Mehta, K. Wynne, K. Meeran.  
Imperial Centre for Endocrinology, Imperial College Healthcare NHS Trust, London.*

**Case 2: It pays to be NOSEY: A case of ACTH-producing nasal ectopic pituitary adenoma**

*Author(s): K Gurazada<sup>1</sup>, A Ihuoma<sup>1</sup>, C Rennie<sup>2</sup>, J Kisalu<sup>1</sup>, B Khoo<sup>1</sup>, N Dorward<sup>3</sup>, T Wilhelm<sup>4</sup>,  
M Galloway<sup>5</sup>, Professor P Bouloux<sup>1</sup>.  
Royal Free Hospital, London*

**Case 3: A severely ill patient with Cushing's disease that escaped medical control**

*Author(s): C T Lim, G Tharakan, N Mendoza, F Roncaroli, A Mehta, N M Martin, K Meeran, T  
Tan  
Imperial Centre for Endocrinology, Imperial College London*

**9:50 Keynote lecture: Cushing's Disease – 100 years on**  
Professor John Newell-Price  
University of Sheffield

**10:35 Forum 1: Challenges during and after pregnancy**  
Chairs: Dr Mark Vanderpump & Miss Joan Grieve

**Case 4: Optimal management of a proposed pregnancy in a patient with acromegaly.**

*Author(s): C. Otti, N.M Martin, D. Papadopoulou, N. Mendoza, F. Roncaroli, A. Falconer, A.  
Mehta, K. Wynne, K. Meeran.  
Imperial Centre for Endocrinology, Imperial College Healthcare NHS Trust, London.*

**Case 5: An Unusual Case of Pituitary Apoplexy Occurring During Pregnancy.**

*Author(s): Tharakan G, Kadiyala R, Damani N, Clements MR and Ostberg JE  
Watford General Hospital*

**Case 6: TSHoma and pregnancy – a management dilemma**

*Author(s): C. Otti, A. Mehta, N.M. Martin, D. Papadopoulou, K. Wynne, K. Meeran.  
Imperial Centre for Endocrinology, Imperial College Healthcare NHS Trust, London.*

**11:25 Coffee and Posters**

11:45

**Forum 2: Apoplexy**

Chairs: Dr Stephanie Baldeweg & Mr Michael Powell

**Case 7: Pituitary Apoplexy post mitral valve replacement-“The mechanism may be different and is there any role for staged surgery, pituitary surgery first followed by cardiac surgery?”**

*Author(s): G Mlawa<sup>1</sup>, M Silveira<sup>2</sup>*

*1. Royal Hampshire County Hospital (Winchester). 2. Southampton Hospital.*

**Case 8: Pituitary Apoplexy in an 88 year old man presenting as acute hyponatraemia with rapid recovery of hypopituitarism following conservative management**

*Author(s): A Falinska, T Htay, M McEwan, M Pelly,*

*D Morganstein, A Wren*

*Best Cell Centre, Chelsea and Westminster Hospital Foundation Trust*

**Case 9: Pituitary Apoplexy Guidelines – We’re seeing better!**

*Author(s): F Olubajo, A Jesurasa, J Newell-Price, R Ross, S Mirza, Saurabh Sinha.*

*Royal Hallamshire Hospital, Sheffield*

12:30

**Reassessing cortisol requirements after pituitary surgery**

Dr Tricia Tan

Imperial College London

13:00

Pituitary Foundation: Joy Ginn (LAPPS)

13:10

**Lunch and Posters**

14:00

**Forum 3: Aggressive pituitary tumours**

Chairs: Dr James Ahlquist and Mr Michael Powell

**Case 10: Histological markers of an unusually aggressive acidophil stem cell pituitary adenoma**

*Author(s): F Talbot<sup>1</sup>, N Stojanovic<sup>2</sup>, J Pollock<sup>2</sup>, F Roncaroli<sup>3</sup> & James Ahlquist<sup>1,2</sup>*

*Southend Hospital, Westcliff on Sea, Essex, <sup>2</sup> Queen’s Hospital, Romford, <sup>3</sup>Neuropathology, Imperial College London.*

**Case 11: Acromegaly due to a massive, invasive pituitary macroadenoma: Management Options**

*Author(s): O’Toole SM, Srirangalingam U, Drake WM, Barts and The London*

**Case 12: 'Refractory thyrotoxicosis' - TSHoma or not?**

*Author(s): O Koulouri<sup>1</sup>, N Kandasamy<sup>1</sup>, C Moran<sup>1</sup>, N Schoenmakers<sup>1</sup>, G Boran<sup>2</sup>, DJ Halsall<sup>1</sup>, N Antoun<sup>1</sup>, VK Chatterjee<sup>1</sup> & M Gurnell<sup>1</sup>*

*University of Cambridge & Addenbrooke’s Hospital, Cambridge, UK<sup>1</sup> Department of Clinical Chemistry<sup>2</sup>, AMNCH, Dublin, Ireland*

**Case 13: An unusually aggressive GH producing pituitary tumour**

*Author(s): J Kisalu<sup>1</sup>; M Murphy<sup>1</sup>; N Dorward<sup>1</sup>; M Galloway<sup>1</sup>; N Fersht<sup>2</sup>; P-M Bouloux<sup>1</sup> <sup>1</sup>Royal Free Hospital, London, UK. <sup>2</sup>UCLH, London, UK*

**Case 14: Diagnosis and Management of Pituitary Germinoma: an unusual cause of sellar mass**

*Author(s) Dr A Garg; Dr S Baldeweg; Dr N Fersht; Miss J Grieve, UCLH, London*

**15:15 Debate: 'This house believes that the case for the preoperative use of somatostatin analogues in patient with acromegaly is proven' ~**

Chairs: Miss Joan Grieve

For the motion: Mr Nick Thomas

Kings College London

Against the motion: Professor William Drake

Royal London Hospital

**16:00 Afternoon tea and Posters**

**16:15 30 years of pituitary surgery**

Mr Michael Powell

University College Hospital London

**16:45 Forum 4 – Audits**

Chairs: Dr Mark Vanderpump & Dr James Ahlquist

**Audit 1: What is the optimal management of pituitary non-functioning adenomas?**

*Author(s): A H Sam, S Shah, A Mehta, J Joshi, K Meeran, N M Martin, S Robinson, J Cox, N Mendoza, A Moolla, F Roncaroli, W S. Dhillon  
Imperial College Healthcare NHS Trust, Imperial College London*

**Audit 2: Prevention better than cure: Post-operative CSF leaks – How can we do better?**

*Author(s): M Horridge, A Jesurasa, F Olubajo, J Newell-Price, S Mirza, S Sinha  
Royal Hallamshire Hospital, Sheffield*

**17:05 Presentation and poster prizes**

Dr Stephanie E Baldeweg

**17:15 Close**

## **Abstracts for orally presented cases**

### **Case 1: Cushing's?**

**Author(s):** Chioma Otti, N.M. Martin, N. Mendoza, F. Roncaroli, A. Mehta, K. Wynne, K. Meeran.  
**Imperial Centre for Endocrinology, Imperial College Healthcare NHS Trust, London.**

A 29-year-old woman was referred in 2008 with oligomenorrhea and hypertension. She described a tendency to bruise easily for 3 years, weight gain, a 5 year history of hirsutism that improved with Dianette and subsequent laser therapy, and mood swings. Examination findings included a BMI of 24.6, blood pressure of 130/80 mmHg, central adiposity, but no evidence of proximal myopathy, bruising or striae. Midnight sleeping cortisol was 546 nmol/l and 9AM ACTH was 27 ng/l. Results of low dose dexamethasone suppression tests (LDDSTs) and cortisol day curves are shown in the table below. Pituitary MRI scan in 2008 was normal, whilst in August 2009 a repeat scan was reported as showing a 5mm discrete region of reduced enhancement. Due to persistent failure to suppress cortisol following LDDST, a diagnosis of ACTH-dependent Cushing's syndrome was made. IPSS in June 2009 revealed a basal central/peripheral ACTH gradient of 0.95 on the left and 1.4 on the right, and peak central/peripheral ACTH of 9.1 on the left and 42 on the right. Due to the biochemical findings (but without progression of symptoms) she underwent trans-sphenoidal surgery in November 2009. However no corticotroph adenoma was identified on post-operative histology. Other causes of hypertension (and congenital adrenal hyperplasia) were sought and excluded. Regular menses commenced post-operatively, with subsequent natural conception and delivery in March 2011. Currently, she is treated solely with amlodipine.

LDDSTs		CORTISOL (nmol/l) DAY CURVES		
Date	48-hr cortisol (nmol/l)	Sample time	June 2009	Oct 2010
Aug 2008	226	0900	452	776
Feb 2009	181	1200	416	680
Mar 2010	92	1500	571	827
Aug 2010	115	1800	281	649
		2100	256	698
			Mean: 415	Mean: 726

#### **Questions for the expert panel:**

- Did this patient ever have Cushing's disease?
- Would you have managed her differently?
- Should we perform repeat dynamic function tests and if so when?

## **Case 2: It pays to be NOSEY: A case of ACTH-producing nasal ectopic pituitary adenoma**

### **Author(s):**

**Kalyan Gurazada<sup>1</sup>, Ajibola Ihuoma<sup>1</sup>, Catherine Rennie<sup>2</sup>, Judith Kisalu<sup>1</sup>, Bernard Khoo<sup>1</sup>, Neil Dorward<sup>3</sup>, Thomas Wilhelm<sup>4</sup>, Malcolm Galloway<sup>5</sup>, Professor Pierre Bouloux<sup>1</sup>.  
Royal Free Hospital, London**

A 19 year old male was diagnosed with Cushing's syndrome in Beirut (2000). Initial investigations suggested a pituitary adenoma, for which he underwent Trans-sphenoidal surgery (TSS); histology however revealed normal pituitary tissue only. Because of the persistence of his disease, a bilateral adrenalectomy soon ensued.

He was then referred to us from Beirut, for further investigations. MRI in 2003 showed a 3mm nodule on the right side of the pituitary. Bilateral inferior petrosal sinus sampling (BIPSS) suggested a pituitary origin of ACTH with right sided preponderance. Trans-sphenoidal resection of the nodule again revealed normal pituitary tissue only. Two years later, with a progressive, though glucocorticoid suppressible rise in ACTH, the patient received radiotherapy to the pituitary bed. Despite this, ACTH continued to rise (>5000ng/L) and the patient became excessively pigmented. A repeat MRI in 2009 showed a mass below the sella turcica in the clivus, resection of which revealed a benign squamous cyst, again with no pituitary tissue.

The following year, after extensive review of previous scans, an abnormal mass was identified in the nasal cavity adjacent to the cribriform plate along the proximal and mid-ethmoidal cells on the left. A designated MRI of the region suggested that this mass was enlarging. Repeat investigations including BIPSS, CRH test and High dose dexamethasone suppression test, however continued to suggest a pituitary origin of the ACTH. Nasal exploration of this abnormal tissue, finally confirmed a pituitary adenoma, with strong immunoreactivity to ACTH. Post-operatively the ACTH fell precipitously to 6.2ng/L, and the excess pigmentation rapidly cleared.

Nasal ectopic pituitary adenomas are rare. Pituitary tissue has been found along the developmental pathway of Rathke's Pouch, which includes the sphenoid sinus, clivus, cavernous sinus and suprasellar region. In our case, the etiology could be an ectopic ACTH pituitary adenoma or an inadvertently implanted pituitary tissue during the initial exploration.

### **Case 3: A severely ill patient with Cushing's disease that escaped medical control**

**Author(s): Chung Thong Lim, George Tharakan, Nigel Mendoza, Federico Roncaroli, Amrish Mehta, Niamh M Martin, Karim Meeran, Tricia Tan**  
**Imperial Centre for Endocrinology, Imperial College London, London**

Hypercortisolism that escapes from control with medical therapies presents particular challenges in severely-ill patients. We present a 57-year old female with severe Cushing's syndrome (CS), characterised by new onset type 2 diabetes mellitus, hypokalaemia, hypertension, weight gain, easy bruising, proximal myopathy, severe depression and slow-healing cellulitic leg ulcers. Investigations confirmed ACTH-dependent CS. LDDST was performed: baseline ACTH 85ng/L, baseline cortisol 907nmol/L, T=48h cortisol 807nmol/L. HDDST showed failure of cortisol suppression to less than 50% baseline: T=0h cortisol 1372nmol/L, T=48h cortisol 825nmol/L. MRI pituitary revealed a left-sided microadenoma. CT chest, abdomen and pelvis did not reveal any potential ectopic source of ACTH. The patient was too unwell for petrosal sinus sampling.

Combined ketoconazole and metyrapone therapy was initiated. However, cortisol levels repeatedly escape from control (>1000nmol/L) despite increases in the dose of both drugs. A subhypnotic infusion of etomidate (2.5mg/h) was therefore commenced but serum cortisol again escaped control despite increases in dose to 5mg/h. Patient also suffered from bowel perforation which was managed surgically but complicated by poor wound healing and dehiscence. The options of bilateral adrenalectomy and pituitary surgery were discussed and she eventually underwent trans-sphenoidal hypophysectomy. Histology confirmed a corticotroph adenoma and post-operatively, she recovered well although her depression persisted despite long-term remission of her Cushing's disease.

Here we report the first case of escape from control with etomidate. Pituitary corticotroph adenomas are theoretically more likely to escape control with medical therapy. This could be due to reduced negative feedback from falling serum cortisol levels resulting in greater ACTH drive, sufficient to overcome pharmacological blockade of cortisol production. This case also raises questions for the expert panel:

- (1) Does HDDST have any place in the investigation of the source of ACTH in ACTH-dependent CS?;
- (2) Has anyone experienced 'escape' from etomidate control in acute emergency management of hypercortisolism?

#### **Case 4: Optimal management of a proposed pregnancy in a patient with acromegaly.**

**Author(s): C. Otti, N.M Martin, D. Papadopoulou, N. Mendoza, F. Roncaroli, A. Falconer, A. Mehta, K. Wynne, K. Meeran.**

**Imperial Centre for Endocrinology, Imperial College Healthcare NHS Trust, London.**

We present a case of a woman who is now 29 years old who initially presented in 2007 with headaches and secondary amenorrhea. Random growth hormone was 780 mu/l (260 mcg/l) and pituitary MRI revealed a macroadenoma with hypothalamic extension and encroachment on the left internal carotid artery. After treatment with sandostatin LAR to attempt tumour shrinkage pre-operatively, she underwent trans-sphenoidal surgery to resect the pituitary macroadenoma twice in 2008. The second operation was complicated by meningitis, from which she made a full recovery. She underwent radiotherapy in 2009 as her growth hormone (GH) levels remained elevated (GH nadir on OGTT 49.9mu/l [16.6 mcg/l], mean GH on a day curve 209 mu/l [70 mcg/l]), and high IGF-1 (132 nmol/l; normal range 13-64). Subsequently lanreotide (Somatuline Autogel) was commenced and her disease was well controlled on 120mg every 3 weeks. However, in November 2011, reassessment of her acromegaly off somatostatin analogues confirmed that her disease was still active (GH nadir on OGTT 7.21 mcg/l, mean GH on day curve 10.72 mcg/l, and IGF-1 62 nmol/l). Therefore lanreotide was continued. Currently, her pituitary axes are intact post-radiotherapy. The most recent MRI of her pituitary (performed in 2011) showed residual tumour with solid enhancement superiorly.

We plan to reassess her GH burden off lanreotide later this year. However she has expressed a desire to start trying to conceive in about 1 year's time.

#### **Questions for the expert panel:**

- What advice should she be given about planning for pregnancy?
- Should lanreotide be continued throughout pregnancy?
- Should lanreotide be stopped during pregnancy and if so at what point should it be stopped?

## **Case 5: An Unusual Case of Pituitary Apoplexy Occurring During Pregnancy.**

**Author(s): Tharakan G<sup>1</sup>, Kadiyala R<sup>1</sup>, Damani N<sup>2</sup>, Clements MR<sup>1</sup> and Ostberg JE<sup>1</sup>**

**<sup>1</sup>.Department of Diabetes and Endocrinology, Watford General Hospital**

**<sup>2</sup>.Department of Radiology, Watford General Hospital**

We present a rare case of pituitary apoplexy occurring in pregnancy. A 34-year old woman was admitted to the obstetric ward with a severe headache in the 38th week of her second pregnancy.

In 2008 the patient was referred with an 8 month history of secondary amenorrhoea and galactorrhoea. Pituitary testing demonstrated a raised prolactin. The initial MRI was reported to show no pituitary tumour, although on later review there is evidence of a small adenoma. Initiation of cabergoline restored menstruation and in June 2010 she became pregnant again.

In the 38th week of her pregnancy she developed severe headaches resulting in an admission for investigation of her symptoms. Her prolactin level was 7131mU/l. Imaging demonstrated a pituitary adenoma measuring 15 by 13 mm with evidence of haemorrhage. There was no evidence of any other pituitary dysfunction. She had no indication for pituitary surgery as described in the UK guidelines for pituitary apoplexy. At 40 weeks of pregnancy the patient underwent an emergency caesarean section. Six months post delivery the patient reported that she and her baby were well. Her prolactin was 1835mU/L with otherwise normal pituitary function and she was still breastfeeding.

Pituitary apoplexy remains a rare event in pregnancy. There are only a handful of cases that describe this clinical entity in the literature. Consequently, there is limited knowledge on how to manage it. Apoplexy has significant morbidity and mortality and appropriate management; whether conservative or surgical can have significant repercussions. This case represents a successful conservative approach.

Our questions for the expert panel are

- (1) If the pituitary apoplexy had occurred earlier in the pregnancy how would the panel have monitored the patient?
- (2) What is their threshold for performing pituitary surgery in a pregnant patient with pituitary apoplexy?

## **Case 6: TSHoma and pregnancy – a management dilemma**

**Author(s): C. Otti, A. Mehta, N.M. Martin, D. Papadopoulou, K. Wynne, K. Meeran.**  
**Imperial Centre for Endocrinology, Imperial College Healthcare NHS Trust, London**

A 31-year-old lady presented with headaches and a brain MRI revealed a large pituitary tumour. She was referred to our centre. She had subtle symptoms of hyperthyroidism. Baseline hormonal profile revealed abnormal thyroid function tests (free T4 22.5 pmol/l [normal range: 9-26], free T3 7.7 pmol/l [normal range: 2.5-5.7], TSH 4.8 mU/l [normal range: 0.3-4.2]), and hyperprolactinaemia 875 mU/l [normal range: 125-625]), with normal levels of other anterior pituitary hormones. Dynamic function tests excluded cortisol deficiency. In July 2011 a pituitary MRI confirmed the presence of a 1.2cm macroadenoma with suprasellar extension without optic chiasm or cavernous sinus involvement.

In view of her thyroid function tests and pituitary mass, the possibility of a TSHoma was raised. There was a flat response to a TRH test (TSH (mU/l): 0 min - 3.64, 30 min - 4.45, 60 min - 3.69), which was consistent with a TSHoma. Furthermore her TSH fell in response to a 100mcg octreotide injection from 3.91 mU/l to a nadir of 2.03 mU/l after 4 hours. Therefore she was commenced on monthly octreotide 20mg injections in August 2011. Pituitary MRI in November 2011 revealed a slight reduction in tumour size. Her most recent thyroid function tests are normal (free T4 20.2 pmol/l, free T3 5 pmol/l, TSH 3.09 mU/l), and her headaches have improved significantly.

The treatment options of long-term octreotide versus trans-sphenoidal surgery have been discussed with her. Due to the fact that she is nulliparous she has opted to defer surgery (and be managed medically) until her family is complete.

### Questions for discussion

- Should octreotide be continued throughout pregnancy to normalise her thyroid function during pregnancy?
- Should octreotide be stopped during pregnancy and if so at what point?
- If we stop octreotide pre-pregnancy, how should her thyroid function be managed in pregnancy?

**Case 7: Pituitary Apoplexy post mitral valve replacement-“The mechanism may be different and is there any role for staged surgery, pituitary surgery first followed by cardiac surgery?”**

**Author(s): G Mlawa<sup>1</sup>, M Silveira**

**<sup>1</sup>.Royal Hampshire County Hospital (Winchester). <sup>2</sup>.Southampton Hospital.**

**Background:** Pituitary apoplexy in a pre-existing pituitary tumour may be caused by haemorrhage, necrosis or ischaemia or combination of the 3. Pituitary apoplexy following cardiac surgery may inflict severe hormonal insufficiency (hypopituitarism) as well as neurological deficit.

**Case:**

A 74 years old retired nurse developed acute confusional state following mitral valve replacement and coronary artery bypass graft (CABG). He also had diplopia which spontaneously resolved. He continued to have polydipsia and polyuria and generalised lethargy. CT brain was normal. MR pituitary was suggestive of pituitary adenoma which may have undergone partial involution. Hormonal profile was suggestive of hypopituitarism. Water Deprivation test was negative and polyuria and polydipsia resolved spontaneously. Short synacthen test was negative 0; 364 nmol/L/l, +30min 764 nmol/L. His past medical history included Hypertension, and high cholesterol. He was started on levothyroxine and testosterone. His current medications are sustanon injection 250mg every 3 weeks, levothyroxine 150mcg daily, ramipril 10mg daily, Adizem XL 240mg daily, Bendrofluazide 2.5mg daily, simvastatin 40mg nocte.

**Discussion:** Pituitary apoplexy may present with headaches, fevers and confusional state visual field defect and ocular palsies. This is due to sudden expansion of pituitary gland or pre-existing pituitary tumour compressing the adjacent cranial nerves and other parasellar structures. Pituitary apoplexy following cardiac surgery may be due to: 1. Haemorrhage due to anticoagulation. 2. Ischaemia and necrosis secondary to low flow state, emboli and haemodilution and absence of pulsatile flow. 3. Tissue swelling might compromise blood supply. 4. A combination of one or more of the above factors.

**Conclusion:**

Pituitary apoplexy following cardiac surgery although rare may occur, and has to be considered as differential diagnosis in patient with headaches or acute confusional state following cardiac surgery.

The mechanism of pituitary apoplexy post cardiac surgery is not exactly the same as apoplexy in patients with pituitary adenoma and haven't undergone cardiac surgery. The mechanism may be multifactorial as explained above.

In patient with known pre-existing pituitary adenoma and needing cardiac surgery (valve replacement/coronary artery bypass graft (CABG)) involvement of endocrinology, neurosurgical team and cardiothoracic surgical team will be beneficial to the patient's best treatment outcome. The case for staged pituitary surgery, followed by cardiac surgery in patient with pre-existing pituitary tumour needing cardiac surgery may be beneficial.

## **Case 8: Pituitary Apoplexy in an 88 year old man presenting as acute hyponatraemia with rapid recovery of hypopituitarism following conservative management**

**Author(s): Agnieszka Falinska, Thein Htay, Michael McEwan, Michael Pelly, Daniel Morganstein, Alison Wren**  
**Best Cell Centre, Chelsea and Westminster Hospital Foundation Trust**

### **Case history**

An 88-year old man presented with hyponatraemia (sodium 118mmol/L). He gave a history of sudden severe headache one week earlier, followed by generalised malaise, disorientation and blurred vision on downward gaze. Past medical history included benign prostatic hypertrophy, atrial fibrillation on warfarin, hypertension, osteoarthritis and previous TIA. Examination revealed subtle left upper quadrantanopia and mild diplopia on left lateral gaze that rapidly resolved.

### **Investigations**

Endocrine investigations were consistent with hypopituitarism affecting adrenal, thyroid, gonadal and growth axes (9am cortisol 55nmol/l; ACTH <5ng/l; TSH 0.33mU/l; fT4 7.9pmol/l; prolactin 112mU/l; LH <0.5U/l; FSH 1.2U/l; testosterone 0.7nmol/l; IGF1 6.6nmol/l). MRI revealed haemorrhage into 17mm pituitary macroadenoma extending to and abutting the optic chiasm and left optic nerve.

### **Treatment and Progress**

Hydrocortisone 100mg qds rapidly improved symptoms and hyponatraemia and dose was tapered. Warfarin was discontinued. Thyroxine 50mcg was added. Low dose testosterone gel was started with PSA monitoring. Apoplexy was managed conservatively as neurological signs resolved. Permanent pacemaker was inserted for bradycardia. Subsequent CT showed resolution of pituitary haemorrhage. Withdrawal of thyroxine and testosterone showed recovery of pituitary function (TSH 2.98mU/l, fT4 11.1pmol/l, testosterone 12.4nmol/l LH 2.3U/l, FSH 5.7U/l, IGF1 13.1nmol/l). 9am cortisol at 214nmol/l suggested possible recovery of HPA axis. Metyrapone suppression test is pending. Warfarin was restarted following pituitary MDT discussion due to high risk of stroke.

### **Conclusions and points for discussion**

Our patient presented with hyponatraemia secondary to hypopituitarism caused by haemorrhage into a previously undiagnosed pituitary macroadenoma with warfarin and hypertension as contributing factors.

Hyponatraemia due to secondary adrenal and thyroid insufficiencies and AVP release due to secondary hypoadrenalism is more common in older patients. Conservative management of pituitary apoplexy can have an excellent outcome with recovery of pituitary function. Warfarin can safely be restarted if stroke risk is high with careful blood pressure management.

## **Case 9: Pituitary Apoplexy Guidelines – We’re seeing better!**

**Author(s):** Farouk Olubajo<sup>1</sup>, Anthony Jesurasa<sup>1</sup>, John Newell-Price<sup>2</sup>, Richard Ross<sup>2</sup>, Showkat Mirza<sup>3</sup>, Saurabh Sinha<sup>1</sup>.

1. Department of Neurosurgery
  2. Department of Endocrinology
  3. Department of Otorhinolaryngology
- Royal Hallamshire Hospital, Sheffield

**Introduction:** In order to encourage good practice in the diagnosis and management of patients with pituitary apoplexy and reduce subsequent morbidity, a group was set up to produce national guidelines. We have audited our recent practice to evaluate the impact of these guidelines.

**Method:** We carried out a retrospective review of all patients presenting with a history of pituitary apoplexy from 2009 onwards to evaluate their management.

**Results:** 10 patients (4F, 6M, age 16 - 68y) were identified with a confirmed diagnosis of pituitary apoplexy. All 5 patients referred after the publication of the guidelines were admitted to our combined endocrine/neurosurgical service in a timely fashion (17h - 4 days) and managed in congruence with the guidelines. 5 patients, who presented before the introduction of the guidelines, were not referred to the appropriate services until at least several days after the onset of symptoms (5 days - several weeks).

Endoscopic pituitary surgery was performed on 6 patients - 5 within 48 hours. 1 patient with a Pituitary Apoplexy Score (PAS) of 2 had urgent surgery for rapidly deteriorating vision. 1 patient had a prolactinoma and was initially managed with cabergoline. Surgery was performed after two weeks for persistent tumour bulk and visual loss.

<b>Median Pituitary Apoplexy Score (PAS)</b>	<b>At presentation</b>	<b>At discharge</b>
<b>Conservative Group</b>	3.5	0.5
<b>Surgical Group</b>	5	2

1 patient in the surgical group died having been in a poor clinical state from a delayed presentation. The remaining patients had an improvement in their vision and general symptoms at discharge.

Of the 4 conservatively managed patients, 3 have had subsequent elective surgery for growing residual tumours.

**Conclusion:** The publication of the UK 2010 guidelines has markedly improved the overall management of patients with pituitary apoplexy. However, visual deterioration remains the key factor in determining whether surgery is indicated.

## **Case 10: Histological markers of an unusually aggressive acidophil stem cell pituitary adenoma**

### **Author(s):**

**Fleur Talbot<sup>1</sup>, Nemanja Stojanovic<sup>2</sup>, Jonathan Pollock<sup>2</sup>, Federico Roncaroli<sup>3</sup> & James Ahlquist<sup>1,2</sup>**

**<sup>1</sup>Endocrine Unit, Southend Hospital, Westcliff on Sea, Essex,**

**<sup>2</sup>Endocrinology and Neurosurgery, Queen's Hospital, Romford,**

**<sup>3</sup>Neuropathology, Imperial College London.**

Although most pituitary adenomas follow a benign course, a small number are particularly aggressive, with local invasion and early recurrence. These aggressive pituitary adenomas can prove very difficult to control. There is growing interest in the management of aggressive pituitary tumours, in particular with the use of temozolomide after surgery and radiotherapy. We present a case where initially histology highlighted the possible need for such therapy early in the course of management.

A 35 year old man presented with loss of vision, VA 6/60 & 6/9 and bitemporal hemianopia, due to a pituitary tumour compressing the optic chiasm. Pituitary function was intact. He underwent trans-sphenoidal pituitary surgery; his vision returned to near normal, and he became cortisol deficient. Histology showed an aggressive pituitary adenoma with mixed amphophilic and eosinophilic staining, and brisk mitotic activity; immunohistochemistry was positive for prolactin (20% of cells) and alpha subunit (10-15%), negative for ACTH, and high proliferation rate was noted (Ki67 8%), with over-expression of P53.

He repeatedly failed to attend clinic and radiotherapy follow up appointments after surgery. Imaging showed significant tumour regrowth over six months, with tumour abutting the optic chiasm. He underwent repeat pituitary surgery with no further loss of pituitary function. Histology showed similar tumour features, with atypical hyperchromatic nuclei, solitary nucleoli and rare giant nuclei also; mitotic figures were again conspicuous, prolactin staining was more prominent, ACTH negative Ki67 5%. Light and electron microscopic features indicate that this is an acidophil stem cell adenoma.

He is currently undergoing pituitary radiotherapy. The neuropathologist raised the question of treatment with temozolomide. This case highlights the unusual features of an aggressive acidophil stem cell adenoma. The panel is invited to comment on the relevance of the histology for early management, and to consider whether detailed pre-emptive treatment with temozolomide should be considered.

## **Case 11: Acromegaly due to a massive, invasive pituitary macroadenoma: Management Options**

**Author(s): O'Toole SM, Srirangalingam U, Drake WM, Barts and The London**

### **Presentation**

A 34 year old carpenter presented with a one year history of lethargy, nasal congestion, debilitating headaches and possible absence episodes. He was noted to appear acromegalic and was referred for endocrinological work-up.

### **Initial investigations and management**

He had typical acromegalic features. There was no visual field defect. Acromegaly was biochemically confirmed: IGF-1 was elevated at 761ng/ml (109-284) and there was failure to suppress serum growth hormone during an oral glucose tolerance test (trough 23.3 mcg/L). Basal pituitary function is shown in the table below.

Free T4	13.6	10.5-24.5 nmol/L	FSH	3.1	1.0-10 IU/L
Total T3	1.7	1-2.7 nmol/L	LH	4.2	1.8-8 IU/L
TSH	1.1	0.3-4 mIU/L	Testosterone	8	9-27 nmol/L
9AM cortisol	321	nmol/L	Prolactin	544	0-496 mIU/L

Magnetic resonance imaging demonstrated a massive tumour filling the sella. The pituitary fossa could not be visualised. There was supra-sellar extension indenting the floor of the third ventricle without hydrocephalus and lateral extension through the left cavernous sinus indenting the medial temporal lobe and hippocampus.

He was commenced on lanreotide 90mg three-monthly and Sustanon 250mg four-weekly. Subcutaneous octreotide 50mcg eight-hourly was concurrently commenced to treat the headache. Leviteracetam was started for a possible diagnosis of temporal lobe epilepsy.

### **Progress**

Headaches remained problematic. Lanreotide was increased to 120mg three-monthly and octreotide was up-titrated to 100mcg six-times daily with substantial symptom relief. The patient discontinued the leviteracetam.

Repeat imaging after four months of therapy showed a significant reduction in tumour volume but with persistent supra-sellar and lateral extension.

### **Discussion**

What should the management of this massive pituitary macroadenoma causing acromegaly be?

- Medical therapy alone?
- Medical therapy followed by debulking surgery – how long should he be pre-treated for and what surgical approach/strategy should be undertaken?
- Medical therapy and EBRT?

## **Case 12: 'Refractory thyrotoxicosis' - TSHoma or not?**

**Author(s): O Koulouri<sup>1</sup>, N Kandasamy<sup>1</sup>, C Moran<sup>1</sup>, N Schoenmakers<sup>1</sup>, G Boran<sup>2</sup>, DJ Halsall<sup>3</sup>, N Antoun<sup>4</sup>, VK Chatterjee<sup>1</sup> & M Gurnell<sup>1</sup>**

**Institute of Metabolic Science<sup>1</sup> and Departments of Clinical Biochemistry<sup>3</sup> and Radiology<sup>4</sup>,  
University of Cambridge & Addenbrooke's Hospital, Cambridge, UK  
Department of Clinical Chemistry<sup>2</sup>, AMNCH, Dublin, Ireland**

A 78-year-old female was referred for further investigation/management of 'refractory thyrotoxicosis'. She had initially presented to another centre ten years earlier and had been found to have raised free thyroid hormone (fT4 and fT3) levels, but with unsuppressed thyrotropin (TSH). Pituitary MRI was reported as normal. She underwent genetic testing for Resistance to Thyroid Hormone (RTH), which was negative. No other affected family members were identified. Her past medical history included hypertension, mitral regurgitation, osteoporosis and coeliac disease. On examination she was very thin (BM1 16kg/m<sup>2</sup>), had a resting tachycardia of 120 bpm SR with a fine tremor, and a palpable smooth goitre.

Investigations confirmed a raised fT4 [46 pmol/l (RR 9-20)] and fT3 [15.1 pmol/l (RR 3.0-7.5)] with inappropriate TSH [1.61mU/l (RR 0.4-4)]. There was no evidence of assay interference. Further profiling revealed: SHBG 188 nmol/l (RR 10-57), alpha-subunit 1.4 mcg/L, with alpha-subunit:TSH molar ratio 8.7 (RR <1), LH 41.3 U/l (RR 16-75), FSH 82.9 U/l (RR 21-140). A TRH test was performed: TSH 0' 0.94 mU/l, TSH 20' 3.2 mU/l, TSH 60' 2.4 mU/l. On the basis of these results she underwent a contrast-enhanced dynamic pituitary MRI with volume acquisition. This identified a possible 3mm pituitary microadenoma.

After discussing treatment options with the patient she was commenced on a trial of depot somatostatin receptor ligand (SRL) therapy. This resulted in complete resolution of her symptoms for the first time in a decade, and was accompanied by normalization of her hyperthyroxinaemia within 3 weeks of the first injection: fT4 56.1 pmol/l (pre) → 12.1 pmol/l (post); fT3 15.2 pmol/l (pre) → 2.9 pmol/l (post); TSH 1.72 mU/l (pre) → 0.26 mU/l (post).

At this stage, the key clinical decision is whether to continue medical therapy or proceed to transsphenoidal surgery.

### Case 13: An unusually aggressive GH producing pituitary tumour

**Author(s):** J Kisalu<sup>1</sup>; M Murphy<sup>1</sup>; N Dorward<sup>1</sup>; M Galloway<sup>1</sup>; N Fersht<sup>2</sup>; P-M Bouloux<sup>1</sup>

<sup>1</sup>Centre for Neuroendocrinology, Royal Free Hospital, London, UK.

<sup>2</sup>Department of Neuro-Oncology, UCLH, London, UK

Last year we reported the case of a 43year old man with an unusually aggressive GH secreting pituitary tumour. We here report on the responses of his tumour to treatment.

**Presenting History:** March 2008, aged 39: Four week history of headache and diplopia. MRI: Large pituitary macroadenoma compressing the chiasm and encasing right internal carotid artery.

#### **Treatment summary till February 2011:**

- TSS surgery x2 (March 2008/ May 2010)
- Radical 3 field R/T (2008)
- Lanreotide/ pituitary replacement (2008)
- Histology: 2008-Atypical sparsely granulated GH producing adenoma. MIBI 5%  
2010: Atypical adenoma. No staining for GH/ pituitary hormones. MIBI>50%
- TSS & Transcranial surgery with Gliadel (carmustine) wafers (Aug/Sept.2010)
- Temozolamide (2010, 1 cycle)
- Anticonvulsants (2010)

#### **Progress:**

	Nov 2011	Oct 2011	Aug 2011	July 2011	Jun 2011	May 2011	Mar 2011	Jan 2011	Mar 2008
<b>GH</b> (mcg/l)	123.6 0	109.5	67.40	27.90	15.50	12.90	38.70	24.0	0.30
<b>IGF-1</b> (10.5- 34.7)	131.8	123.4	97.6	98.7	95.9	105.2	125.5	133.0	106.9

**MRI March:** significant increase in tumour size. **April:** suprasellar and left cavernous component smaller **August:** marked distortion of pons, midbrain and cranial nerves.

**Octreotide scan September:** Avid tumour uptake of radionuclide. Progressive tumour spread along left 5<sup>th</sup> nerve with brainstem metastasis.

**September:** Bilateral cranial nerve palsies. Sensory loss in V1 bilaterally. Ophthalmoplegia. Blindness right eye. Passive eye closure. No limb weakness. Facial pain/ paraesthesia.

**November:** Limited movement of left eye, a little elevation and depression possible. Right: total ophthalmoplegia. Speech: not dysphasic. Swallowing: some difficulty. Taste: preserved. Mobility: room to room with help. Epistaxis/nasal discharge- tumour visible. Episodic confusion.

#### **Treatment February –December 2011:**

- Cyberknife: *Feb*
- VP shunt: *Sept*
- Lutetium-17: *Oct– Dec*

Despite the above and demonstration of avid tumour uptake of radio-labelled octreotide, there was no response to treatment. Neurological deterioration and enlargement of brain stem metastases lead to death (16<sup>th</sup> December).

## **Case 14: Diagnosis and Management of Pituitary Germinoma: an unusual cause of sellar mass**

**Author(s) Dr A Garg; Dr S Baldeweg; Dr N Fersht; Miss J Grieve, UCLH, London**

Germinomas are malignant intracranial tumors with peak incidence in children and adolescents. They are usually localised in midline central nervous system structures, most frequently in pineal gland. This case highlights the presentation, line of investigation and management of such a case.

Mr AS, 23 year old gentleman of Somalian origin reported of headache of few months and visual disturbances. He was referred to eye specialist by optician. He was admitted at National Hospital for Neurology and Neurosurgery for further investigations in view of bitemporal hemianopia and large sellar mass on CT Brain. On further assessment, he complained of weight loss and polyuria and polydipsia but no galactorrhoea. His MRI showed a large intra and suprasellar mass involving left cavernous sinus and elevating the chiasm and reaching into third ventricle. It enhanced avidly. The pituitary was seen to be compressed and there was enhancement of pineal gland, more in keeping with germ cell tumor. Biochemical assessment confirmed Diabetes Insipidus, hypothyroidism and cortisol deficiency. He was started on steroid replacement, thyroxine and desmopressin.

Tumor markers showed an elevated beta HCG. Alpha fetoprotein was normal. CSF beta HCG was also elevated.

He underwent transphenoidal biopsy with some debulking of lesion. Histopathology confirmed the diagnosis of Germinoma.

He underwent craniospinal radiotherapy at UCH.

## **Audit 1: What is the optimal management of pituitary non-functioning adenomas?**

**Author(s): Amir H. Sam, Sachit Shah, Amrish Mehta, Jay Joshi, Karim Meeran, Niamh M Martin, Stephen Robinson, Jeremy Cox, Nigel Mendoza, Ahmad Moolla, Federico Roncaroli, Waljit S. Dhillon**

**Imperial Centre for Endocrinology, Imperial College Healthcare NHS Trust, Imperial College London**

**Case 1.** A 28-year woman with a 10 mm pituitary non-functioning adenoma (NFA) is seen in the Endocrine clinic. There is no evidence of optic chiasm compression. Should she be managed conservatively or offered trans-sphenoidal surgery?

**Case 2.** A 41-year-old woman with a non-functioning pituitary macroadenoma compressing the optic chiasm is treated with trans-sphenoidal surgery. Post-operative MRI shows residual tumour away from the optic chiasm. Should she be followed up with observation alone or offered trans-sphenoidal surgery and/or radiotherapy?

The natural history and the optimum management of pituitary NFAs remain unclear. We carried out a retrospective study of the patients with pituitary NFAs who were either managed conservatively or surgically without postoperative radiotherapy at our centre. Inclusion criteria included: radiological evidence of a pituitary adenoma and absence of clinical /biochemical evidence of hormone hypersecretion. The pituitary imaging for all patients was re-examined by a single experienced neuroradiologist. Patients with a radiological follow-up period of less than 1 year and those presenting with apoplexy were excluded. One hundred and seven patients with NFAs were included in this study.

Sixty patients were managed conservatively for a mean follow-up period of 4 years (range: 1-14.7). Forty-one (68.3%) were macroadenomas and 19 (31.7%) were microadenomas. A reduction in the tumour size was observed in 20 (33.3%) patients and the tumour remained stable in 8 (13.3%) patients at the end of the follow-up period. In the 32 patients with tumour enlargement, the average time for the first evidence of tumour growth was 2.1 years (range: 0.4-7.5). The average annual growth rate was 0.9 mm per year (range: 0.1- 4.3). One patient developed a visual field defect after a follow-up period of 14.7 years and was treated surgically. Eight out of seventeen (47%) patients with adenomas 5-10 mm in size showed tumour size reduction/ no further growth during the follow-up period. Ten out of eighteen (55.6%) patients with adenomas > 10 mm and not impinging on the optic chiasm had tumour reduction/ no further growth during the follow-up period. Twenty patients with pituitary NFA contacting the optic chiasm at presentation did not undergo surgery either due to presence of comorbidities or because patient was not keen for surgery.

Forty-seven patients were treated surgically. The pituitary NFA contacted the optic chiasm in all patients. The average tumour size in this group was 31.7 mm (13-51.2). The mean post-operative follow-up period was 6.2 years (range: 1-19.4). Forty-five patients (95.7%) had residual tumour post-operatively. No tumour enlargement was seen in 22 (46.8%) patients during the follow-up period. In the 25 patients with evidence of recurrence, the average time to first radiological sign of tumour enlargement was 3.2 years (range: 0.5-12.2 year). Seven patients (14.9%) had a second operation or further recurrence of optic chiasm compression.

**Question for the expert Panel:** In light of this study, what is the optimal management for the 2 cases detailed above?

## **Audit 2: Prevention better than cure: Post-operative CSF leaks – How can we do better?**

**Author(s):** Michelle Horridge<sup>1</sup>, Anthony Jesurasa<sup>1</sup>, Farouk Olubajo<sup>1</sup>, John Newell-Price<sup>2</sup>, Showkat Mirza<sup>3</sup>, Saurabh Sinha<sup>1</sup>

1. Department of Neurosurgery
2. Department of Endocrinology
3. Department of Otorhinolaryngology

Royal Hallamshire Hospital, Sheffield

### **Introduction:**

Post-operative CSF leak remains the bane of the pituitary surgeon's practice, occurring in 10-20% with the subsequent risk of meningitis. Our recent endoscopic experience has led to a routine use of the pedicled naso-septal flap (NSF) as a primary repair for intra-operative CSF leaks to reduce this complication.

### **Method:**

We carried out a retrospective review of all patients undergoing trans-sphenoidal surgery for pituitary disease from January 2008 to present. Prior to September 2009, 43 cases were performed microscopically (MTSS) and since then 82 cases endoscopically (ETSS).

### **Results:**

In the MTSS group intra-operative CSF leaks were all repaired with fat graft, tisseal and lumbar drain insertion. Intra-operative leaks in the ETSS group were routinely repaired with a pedicled naso-septal flap. Lumbar drains are no longer used.

A naso-septal flap could no longer be harvested in patients who had previous trans-sphenoidal surgery (PTSS). In patients requiring endoscopic surgery for recurrent tumour, intra-operative repair was fashioned using fat graft and duraseal.

	<b>No. of Patients</b>	<b>Post-op CSF leak</b>	<b>%</b>	<b>Length of stay (mean)</b>
<b>MTSS</b>	<b>43</b>	<b>5</b>	<b>11.6%</b>	<b>11 days</b>
<b>PTSS</b>	<b>16</b>	<b>4</b>	<b>25%</b>	<b>17 days</b>
<b>ETSS</b>	<b>66</b>	<b>1</b>	<b>1.5%</b>	<b>9 days</b>

Post-operative CSF leak rates are shown above. Lumbar drainage was used in the management of patients in the MTSS and PTSS groups. 2 patients in the PTSS group required shunts for persistently raised CSF pressure.

1 patient in the ETSS group developed constipation and had a CSF leak on straining. The patient returned to theatre, where it was noted that the naso-septal flap had moved away from the sellar defect. The flap was re-positioned and duraseal used to aid the repair.

### **Conclusion:**

The advent of the pedicled naso-septal flap conveys a significant advantage in preventing CSF leak, thus decreasing post-op morbidity and shortening hospital stay.